Neurointervention 2023;18:63-66
https://doi.org/10.5469/neuroint.2022.00486

Novel Superior Cerebellar Artery Aneurysm Coming from a Superior Cerebellar Artery-Posterior Cerebral Artery Anastomotic Branch

Anthony V. Nguyen, MD, Ethan A. Benardete, MD, PhD

Department of Neurosurgery, Baylor Scott and White Health, Temple, TX, USA

A middle-aged patient presented with subarachnoid hemorrhage and was found to have a ruptured superior cerebellar artery (SCA) aneurysm arising from the origin of a rare anastomotic branch between the right SCA and right posterior cerebral artery (PCA). The aneurysm was secured by transradial coil embolization, and the patient made a good functional recovery. This case demonstrates an aneurysm arising from an anastomotic branch between the SCA and PCA, which may represent a remnant of a persistent primordial hindbrain channel. Although variations in basilar artery branches are common, aneurysms rarely can form at the site of seldom-seen anastomoses between the branches of the posterior circulation. The complex embryology of these vessels, which includes anastomoses and the involution of primitive arteries, may have contributed to the development of this aneurysm arising from an SCA-PCA anastomotic branch.

Key Words: Intracranial aneurysm; Superior cerebellar artery; Anatomical variation; Subarachnoid hemorrhage; Embryology

Correspondence to:
Ethan A. Benardete, MD, PhD
Department of Neurosurgery, Baylor Scott and White Health, 2401 S. 31st Street, MS-01-E549, Temple, TX 76508, USA
Tel: +1-215-275-7589
Fax: +1-254-724-5779
E-mail: Ethan.Benardete@BSWHealth.org

Received: December 26, 2022
Revised: February 11, 2023
Accepted: February 13, 2023

pISSN 2093-9043
eISSN 2233-6273

INTRODUCTION

Superior cerebellar artery (SCA) aneurysms represent less than 2% of intracranial aneurysms in most series.[1] We describe a case of a patient with a ruptured SCA aneurysm that arose from the origin of an unusual anastomotic branch connecting the lateral segment of the SCA and the P1 segment of the posterior cerebral artery (PCA). The embryology of the posterior circulation is complex, involving the fusion and involution of various vascular channels during fetal development.[2] The complex embryology of the distal basilar artery, its branches, and the PCA are likely involved in the origin of this branch and the aneurysm.

CASE REPORT

A middle-aged patient with a past medical history of hypertension and hyperlipidemia initially presented to an outside facility after being found unresponsive. The patient was transferred to our institution for management of subarachnoid hemorrhage (SAH). A computed tomography (CT) scan of the head performed at our facility demon-

strated extensive, thick SAH with intraventricular extension (Fig. 1A). There was no history of antiplatelet or anticoagulant use nor a family history of aneurysms. The patient was not a user of tobacco, alcohol, or illicit drugs. The initial Glasgow Coma Score (GCS) was 6, and an external ventricular drain was placed.

Initial work-up consisting of CT angiography (CTA) and catheter-based cerebral angiography demonstrated an anastomotic vessel between the right SCA and PCA, but there was no suggestion of an aneurysm. A CTA was repeated on post-bleed day 7, which revealed an aneurysm at the origin of the anastomotic vessel between the proximal SCA and the P1 segment of the PCA. Catheter angiography with 3D reconstruction confirmed a 4.5 mm×2.5 mm×2.0 mm aneurysm arising from the origin of this anastomotic vessel (Fig. 1B–D). A microcatheter was inserted into the proximal right SCA, and microcatheter angiography confirmed the relationship between the unusual vessel and the neck of the aneurysm, as filling of the SCA, PCA, and aneurysm were all seen *via* a run from the proximal right SCA (not shown). CTA showed the relationship between the posterior communicating artery, the aneurysm, and the anastomotic branch (Fig. 1E). The aneurysm was catheterized and successfully treated by trans-radial coil embolization with Raymond–Roy occlusion class I (Fig. 1F). The anastomotic vessel now filled retrograde from the right PCA since the origin of the

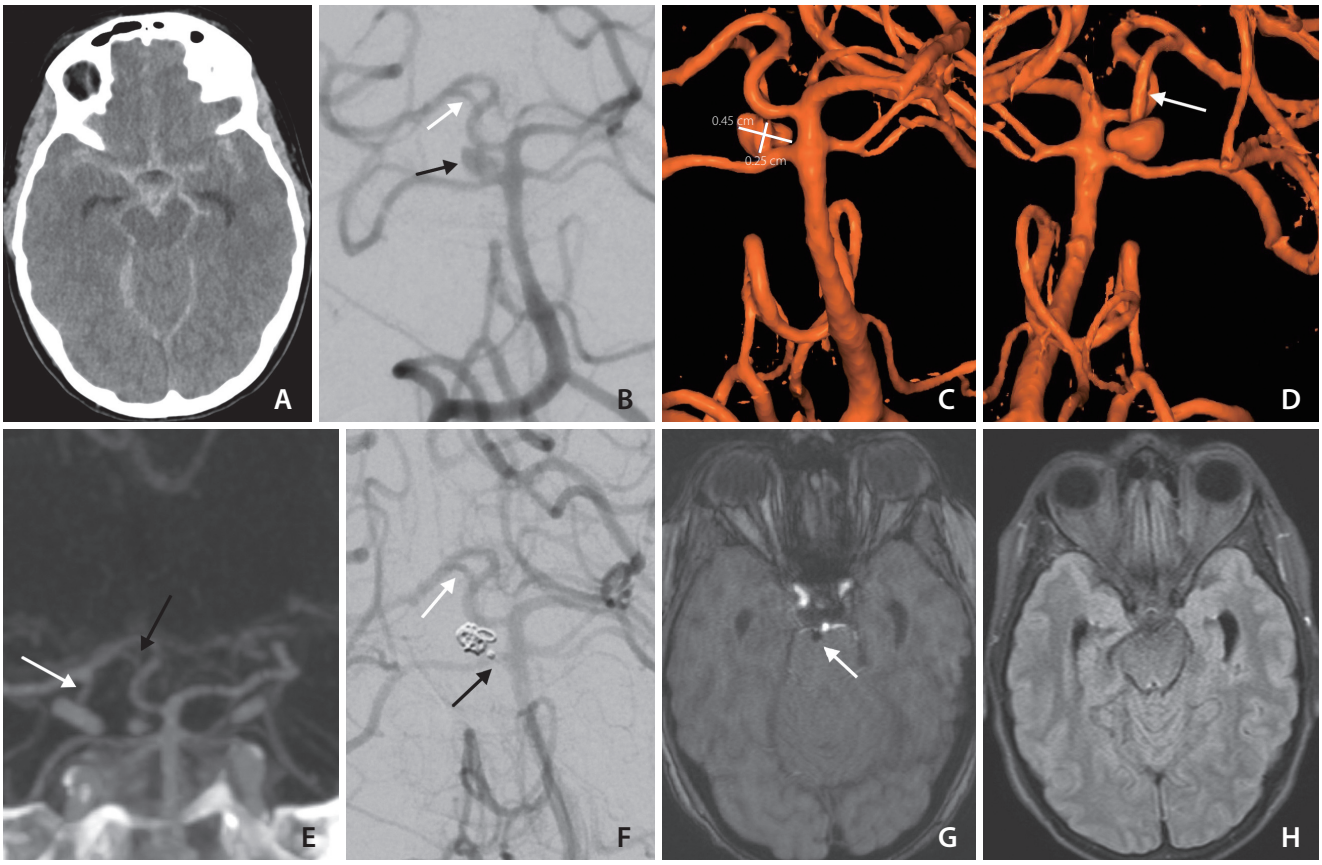

Fig. 1. (**A**) Computed tomography (CT) of the head demonstrating diffuse subarachnoid hemorrhage. (**B**) Catheter-based angiography approximately 1 week after presentation with subrachnoid hemorrhage demonstrating an aneurysm (black arrow) arising from the superior cerebellar artery (SCA)-posterior cerebral artery (PCA) anastomotic branch (white arrow). (**C**) Anterior-posterior view of 3D rotational angiography demonstrates a 4.5 mm×2.5 mm aneurysm that shares a neck with the SCA-PCA branch origin and is posterior to the SCA-branch junction. (**D**) Posterior-anterior view of 3D rotational angiography provides an alternate view of the aneurysm and the SCA-PCA branch (white arrow). (**E**) CT angiogram of the head with thick cut maximum intensity projection coronal slice demonstrating the SCA-PCA anastomotic branch (black arrow) and posterior communicating artery (white arrow). The posterior communicating artery is clearly separate from the anastomotic branch and joins the PCA more distally than the branch. (**F**) Raymond–Roy 1 occlusion of the aneurysm with coils (white arrow); still visible is the anastomotic branch between the SCA and PCA (black arrow). (**G**) Magnetic resonance imaging (MRI) angiography axial slice demonstrating the position of the coils (white arrow). (**H**) MRI T2/fluid-attenuated inversion recovery axial slice without evidence of ischemia.

anastomotic vessel along with the aneurysm was occluded. Follow-up clinical exam and magnetic resonance imaging (MRI) did not demonstrate any stroke related to treatment.

After a prolonged stay in the intensive care unit and inpatient rehabilitation, the patient was discharged and followed up in the neurosurgery clinic. The patient returned home with a modified Rankin score of 2. Follow-up MRI performed 5 months after SAH demonstrated no evidence of ischemia or aneurysm recurrence (Fig. 1G, H).

DISCUSSION

This case represents a novel observation of a previously undescribed aneurysm arising from the origin of an anastomotic branch between the SCA and PCA. The location of this aneurysm is unique, but it was possible to treat this aneurysm with standard trans-radial coil embolization without complication, and the patient recovered well. Since we hypothesize that this unusual vessel and the aneurysm formed from a variation in the development of the distal basilar artery and the SCA, we briefly discuss the embryology of the basilar artery and its branches here.

The SCAs are considered the most consistent infratentorial intracranial arteries, and they are embryologically derived from the caudal divisions of the internal carotid arteries.[2,3] There are many reported variations of the vertebrobasilar system and the posterior cerebral arteries, including fenestrations, duplications (even triplications), and common origins of vessels.[2,4] This variety is due, in part, to the dual origin of the basilar artery. The portion of the basilar artery proximal to the trigeminal artery origin is formed by fusion of the 2 dorsal longitudinal neural arteries, which are derived from the primordial hindbrain channel, and the distal basilar is formed by fusion of the caudal divisions of the internal carotid artery.[2,5] Abnormalities in fusion can result in anatomic variations of the PCA and SCA.

During the embryological development of the posterior circulation, multiple anastomotic channels and plexiform networks of vessels develop and involute. The primordial hindbrain channel develops into the longitudinal neural arteries and the primitive lateral basilovertebral anastomosis of Padget.[5] The longitudinal neural arteries fuse at the midline to form the basilar artery, and perforating vessels branch off. The primitive lateral basilovertebral anastomosis runs parallel to the basilar artery and ends cranially at the SCA. Persistence of this anastomosis has been described in the literature in a patient with a ruptured aneurysm.[6]

Persistent primordial hindbrain channels can travel even more rostral than the primitive lateral basilovertebral anastomosis and can result in a conduit between the SCA and the PCA if they fail to involute, although this phenomenon is rare.[5] This conduit appears as an anastomotic vessel from the SCA to the PCA in addition to the normal anatomy. We believe that this situation explains the unusual vessel in this case.

As an alternative explanation, we considered whether a fusion abnormality ("fenestration") of the basilar artery or a duplication of the distal basilar artery was present in this case. However, the variant we observed does not have the appearance of these distal basilar anomalies, which most commonly consists of an "unzipped" distal basilar with acute angulation of the PCAs.[7,8] Additionally, the anastomotic vessel arises from the proximal SCA, not the basilar artery. This unique aneurysm is consistent with prior observations that persistent embryological arteries are associated with saccular aneurysms.[9]

We also considered the possibility that the aneurysmal dilatation of the SCA-PCA conduit represented a dissection of this unusual vessel instead of a saccular aneurysm. These 2 alternatives are difficult to distinguish with current imaging; however, the anastomotic branch distal to the aneurysm maintained a regular luminal diameter and did not have the appearance of a dissected vessel. The right SCA also appeared normal. We favor the idea that the branch point between the right SCA and the anastomotic artery formed an aneurysm in accordance with Rhoton's rule that aneurysms form at branch points and at acute arterial bends.[10]

The authors herein described a novel ruptured aneurysm arising from an SCA-PCA anastomotic branch and considered how the elaborate embryology of the distal basilar complex likely contributed to the presence of this vessel and aneurysm. Despite this aneurysm's unique location, treatment was possible endovascularly, and the patient made a good recovery.

Fund
None.

Ethics Statement
This report was written in concordance with the Baylor Scott & White Institutional Review Board. The requirements for In-

stitutional Review Board approval and consent were waived. We removed all identifiable patient information to ensure anonymity.

Conflicts of Interest

The authors have no conflicts to disclose.

Author Contributions

Concept and design: AVN and EAB. Analysis and interpretation: AVN and EAB. Data collection: AVN and EAB. Writing the article: AVN and EAB. Critical revision of the article: AVN and EAB. Final approval of the article: AVN and EAB.

ORCID

Anthony V. Nguyen: https://orcid.org/0000-0002-3566-2659
Ethan A. Benardete: https://orcid.org/0000-0001-7341-3744

REFERENCES

1. Korja M, Kivisaari R, Rezai Jahromi B, Lehto H. Size and location of ruptured intracranial aneurysms: consecutive series of 1993 hospital-admitted patients. *J Neurosurg* 2017;127:748-753
2. Lasjaunias P, Berenstein A, ter Brugge KG. Surgical neuroangiography, 2nd ed. Springer; 2001
3. Aydın ME, Kaya AH, Kopuz C, Demir MT, Corumlu U, Dagcinar A. Bilateral origin of superior cerebellar arteries from the posterior cerebral arteries, and clues to its embryologic basis. *Anat Cell Biol* 2011;44:164-167
4. Caruso G, Vincentelli F, Rabehanta P, Giudicelli G, Grisoli F. Anomalies of the P1 segment of the posterior cerebral artery: early bifurcation or duplication, fenestration, common trunk with the superior cerebellar artery. *Acta Neurochir (Wien)* 1991; 109:66-71
5. Gregg L, Gailloud P. The role of the primitive lateral basilovertebral anastomosis of padget in variations of the vertebrobasilar arterial system. *Anat Rec (Hoboken)* 2017;300:2025-2038
6. Ota T, Dofuku S, Sato M. Persistence of primitive lateral basilovertebral anastomosis with a ruptured posterior inferior cerebellar artery aneurysm: a case report. *NMC Case Rep J* 2022;9:69-72
7. Tanaka M, Kikuchi Y, Ouchi T. Neuroradiological analysis of 23 cases of basilar artery fenestration based on 2280 cases of MR angiographies. *Interv Neuroradiol* 2006;12(Suppl 1):39-44
8. Klostranec JM, Krings T. Cerebral neurovascular embryology, anatomic variations, and congenital brain arteriovenous lesions. *J Neurointerv Surg* 2022;14:910-919
9. Menshawi K, Mohr JP, Gutierrez J. A functional perspective on the embryology and anatomy of the cerebral blood supply. *J Stroke* 2015;17:144-158
10. Rhoton AL Jr. Aneurysms. *Neurosurgery* 2002;51(4 Suppl): S121-S158