

A Case of Severe Delayed Vasospasm after Clipping Surgery for an Unruptured Intracranial Aneurysm

Joong-Goo Kim, MD^{1,2}, Chul-Hoo Kang, MD^{1,2}, Jae Jon Sheen, MD, PhD³, Yunsun Song, MD, PhD⁴, Jong-Kook Rhim, MD, PhD³

¹Jeju National University School of Medicine, Jeju, Korea

²Department of Neurology, Jeju National University Hospital, Jeju National University College of Medicine, Jeju, Korea

³Department of Neurosurgery, Jeju National University Hospital, Jeju National University School of Medicine, Jeju, Korea

⁴Department of Radiology, Asan Medical Center, University of Ulsan College of Medicine, Seoul, Korea

Delayed ischemic stroke associated with intractable vasospasm after clipping of unruptured intracranial aneurysms (UIAs) has been rarely reported. We report a patient with delayed ischemic stroke associated with intractable vasospasm following UIA clipping. A middle-aged female underwent surgery for unruptured middle cerebral artery bifurcation aneurysms. The patient tolerated the neurosurgical procedure well. Seven days postoperatively, the headache was unbearable; a postcraniotomy headache persisted and abruptly presented with global aphasia and right-sided hemiplegia after a nap. Emergency digital subtraction angiography showed severe luminal narrowing with segmental vasoconstriction, consistent with severe vasospasm. The patient's neurological deficit improved after chemical angioplasty. Neurosurgeons should pay close attention to this treatable/preventive entity after neurological deterioration following UIA clipping, even in patients without subarachnoid hemorrhage.

Key Words: Aneurysm; Angioplasty; Headache; Ischemic stroke

INTRODUCTION

With the recent development of neuroimaging techniques, such as computed tomography (CT) and magnetic resonance imaging (MRI), the detection of unruptured intracranial aneurysms (UIAs) is rapidly increasing.¹ The prevalence of UIAs is estimated to be 3.2%, and UIAs are the leading cause of non-traumatic subarachnoid hemorrhages (SAHs). The fatality rate of patients after rupture of intracranial aneurysms has been estimated to be approximately 50%.² Thus, depending on the location, size, and morphology of the UIA, imple-

menting the best strategies to prevent grave SAH is crucial.³ Although limitations to the interventional approach have progressively decreased due to increasing expertise and some technical refinements, aneurysmal clipping is still regarded as the best therapeutic option for middle cerebral artery (MCA) bifurcation aneurysms among neurosurgeons.⁴ Also, surgical clipping for UIA treatment has shown greater advantages in terms of safety and efficacy due to the specific anatomical characteristics of the MCA bifurcation complex.⁵ Moreover, the risk of perioperative complications has significantly decreased compared to that

Correspondence to:

Jong-Kook Rhim, MD, PhD

Department of Neurosurgery, Jeju National University Hospital, Jeju National University School of Medicine, 15 Aran 13-gil, Jeju 63241, Korea

Tel: +82-64-717-1620

Fax: +82-64-717-1630

E-mail: nsrhim@gmail.com

Received: April 8, 2024

Revised: May 25, 2024

Accepted: June 3, 2024

Copyright © 2024 Korean Society of Interventional Neuroradiology

This is an Open Access article distributed under the terms of the Creative Commons Attribution Non-Commercial License (<http://creativecommons.org/licenses/by-nc/4.0>) which permits unrestricted non-commercial use, distribution, and reproduction in any medium, provided the original work is properly cited.

pISSN 2093-9043

eISSN 2233-6273

in the past due to the development of microscopic surgery and advanced neuro-anesthesia techniques.⁶ Importantly, treating UIAs rarely causes ischemic brain damage associated with vasospasm, so managing patients with UIA has led to much better clinical outcomes than treating patients after rupture. Nevertheless, ischemic events following unpredictable delayed vasospasm after clipping have been reported in UIA patients.⁷⁻²⁰ Here, we report a case in which delayed vasospasm and ischemic stroke accompanied by intractable headache occurred 1 week after the successful clipping of an unruptured MCA bifurcation aneurysm.

CASE REPORT

A middle-aged patient without any comorbidities received a brain MRI at the neurology department following an episodic headache. The patient denied any other neurological symptoms, and the patient neurological examination was normal. Initial MR angiography and digital subtraction angiography (DSA) demonstrated an incidental 3.7×2.2 mm

aneurysm with a bleb in the dome arising from left MCA bifurcation (Fig. 1A). The patient opted to visit another hospital, and after a discussion with the neurosurgeon, the patient decided to undergo elective clipping of the left MCA bifurcation aneurysm. Postoperatively, the patient was transferred to the neurointensive care unit and briefly experienced a single seizure episode. The patient tolerated the neurosurgery well and was discharged on postoperative day 3 with residual headache. However, at 7 days postoperative, the patient was admitted to the local hospital to manage an unbearable, sustained postcraniotomy headache without any neurological deficits. On day 3 after admission, the headache was well managed with a painkiller, and the patient presented with global aphasia and right-sided hemiplegia after a nap. Neuroimaging studies with pre-enhanced CT and diffusion-weighted brain images revealed severe left MCA territory infarction (Fig. 2A–C). Thus, the patient was transferred to a comprehensive stroke center, and a novel perfusion MRI revealed decreased cerebral flow throughout the left MCA region.

Next, an emergent DSA was performed, and the initial

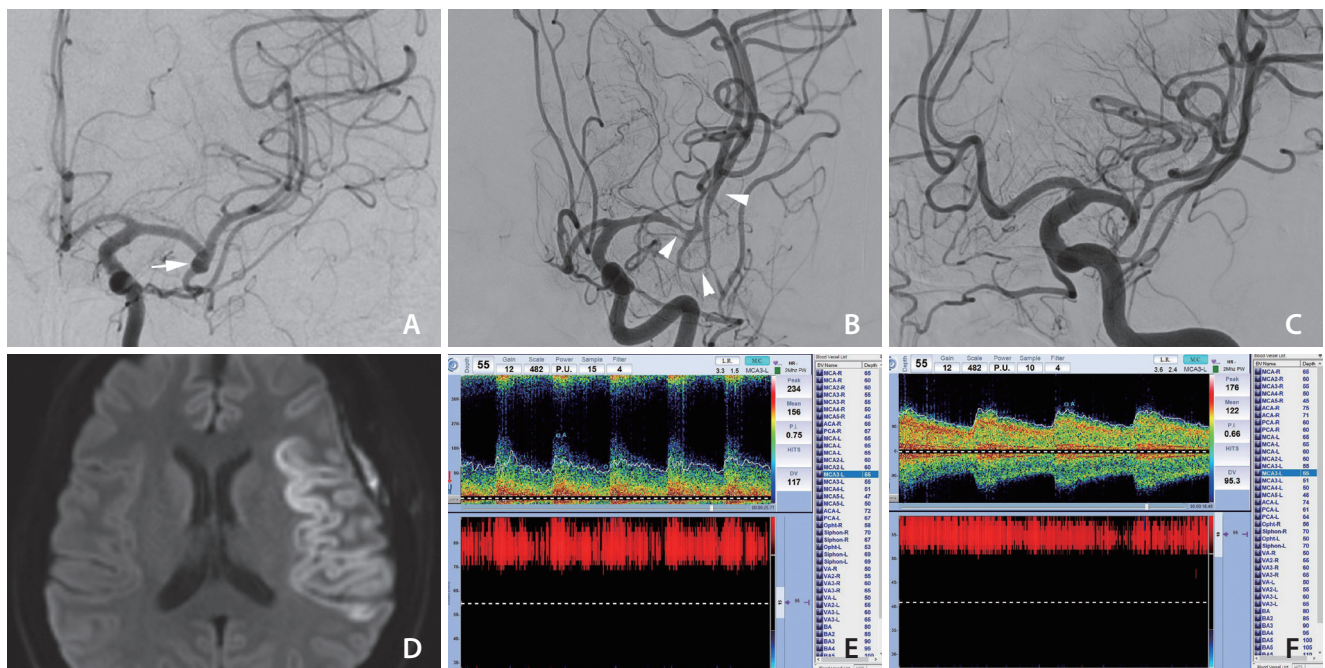


Fig. 1. Digital subtraction angiography (DSA) findings and transcranial Doppler changes before and after treatment. (A) DSA image showing a normal vascular diameter and normal vascular appearance at the initial exam. Contrast stagnation was observed at the left middle cerebral artery (MCA) bifurcation, suggesting an unruptured saccular aneurysm (white arrow). (B) Severe luminal narrowing around the MCA bifurcation (white arrowheads) and overdilated M2–3 segments were observed on DSA at the first neurologic deterioration. (C) Marked resolution of vasospasm was shown after intraarterial nimodipine. (D) Diffusion restriction at the left MCA territory was confirmed at the transferred hospital. (E) The mean flow velocity was increased (156 cm/s, 55 mm) and the Lindegaard ratio was 5, which are indicative of moderate to severe vasospasm. (F) Improvement of vasospasm was shown by transcranial Doppler monitoring after 2 nimodipine injections.

angiography revealed severe luminal narrowing with segmental vasoconstriction, which suggested severe vasospasm (Fig. 1B). Intraarterial nimodipine was instilled after internal carotid artery selection (5 mg twice for the initial 2 days) with angiographic control showing a marked improvement in the caliber of these segments. To optimize cerebral blood flow, systemic norepinephrine (target blood pressure 160–200 mmHg) was added. The patient was admitted to the neuro-intensive care unit and received volume expansion and permissive hypertension treatment. One day later, a repeat DSA showed mild improvement in the vasospasm in the same vessel. The patient received an additional 5 mg of intraarterial nimodipine again with marked improvement in vasospasm (Fig. 1C). Transcranial Doppler monitoring of the MCA vasospasm revealed improvements in the mean flow velocity and Lindegaard ratio after intraarterial treatment (Fig. 1E, F). Unfortunately, the patient MRI showed an infarction involving the left MCA region (Fig. 1D). The patient's neurological status gradually improved after chemical angioplasty. The patient was able to live independently, but prominent motor dysphasia was still present until hospital discharge.

DISCUSSION

Cerebral vasospasm, which is relatively uncommon, has been reported to occur after the clipping of a UIA.⁷⁻²⁰ Here, we reported a case of a middle-aged female who suffered from an

ischemic stroke due to severe vasospasm following successful treatment of an unruptured MCA bifurcation aneurysm. The pathomechanism of the unexpected severe vasospasm remains unclear. Because the etiology of cerebral vasospasm can vary, the underlying mechanisms are likely multifactorial. Even the exact mechanism of vasospasm following SAH is still not completely understood. Several potential mechanisms have been identified that may regulate or reflect the pathogenic alterations of cerebral vessels in vasospasm, such as (1) dysregulation of cerebral vascular tone, (2) sympathetic overactivity, (3) endothelial dysfunction, (4) excessive oxidative stress, and (5) blood-brain barrier disruption.^{21,22} The breakdown of products from injured erythrocytes, such as oxyhemoglobin in the aneurysmal sac, has been considered an inducer of vasospasm.²¹ Mechanical manipulation around the major branches of the MCA may lead to impaired cerebrovascular reactivity, which induces a vasospastic response. The trigeminal-cerebrovascular system has also been regarded as a potential risk factor for cerebral vasospasm. The activation of trigeminal sensory nerves around the circle of Willis releases vasoactive molecules, resulting in cerebral vasodilation to maintain a normal vessel diameter.^{9,21} Cerebral vasospasm does not occur exclusively in SAH and can be observed in patients with subdural hematoma following hematoma evacuation, intracranial tumor resection, or traumatic brain injury.²³

Postcraniotomy headaches are a common symptom after surgery, and most of the time they can be completely re-

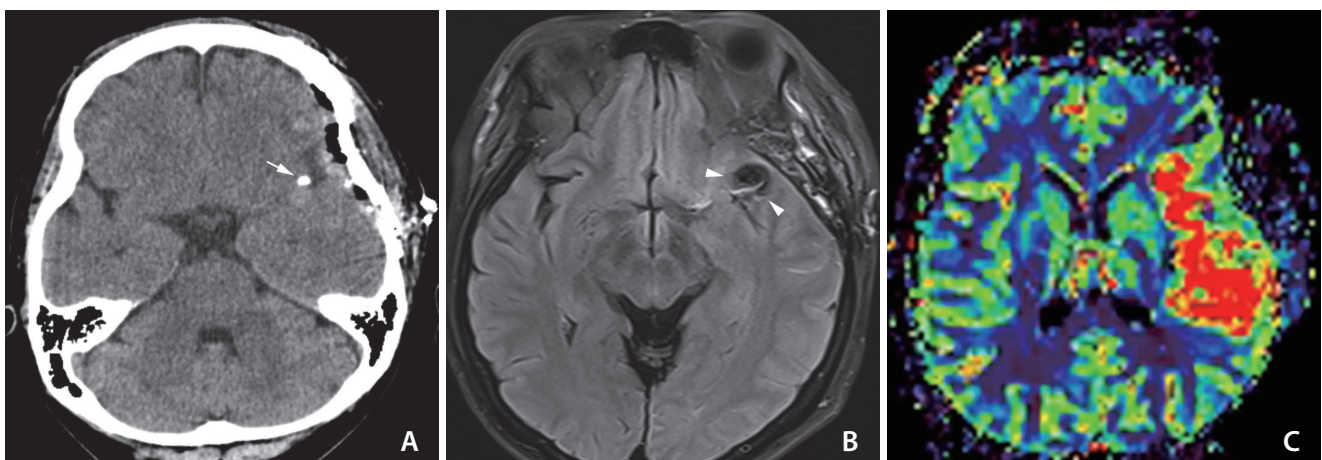


Fig. 2. Initial neuroimages of the patient at the ischemic symptom onset. **(A)** Computed tomography scan demonstrates the successful clipping of the left middle cerebral artery (MCA) bifurcation aneurysm without significant hyperacute stroke. Very bright, high signal intensity at the left Sylvian fissure regarding the metal clip artifact was observed (white arrow). **(B)** Some suspicious hyperintense vessel signs on the fluid attenuated inversion recovery image suggested that ischemic changes (white arrowheads) are noted in the left Sylvian region and temporal lobe. **(C)** Magnetic resonance perfusion showing marked increased mean transit time in the left MCA distribution.

Table 1. Summary of reported cases

Study (y)	Location	Size	Postop headache	Symptom	POD	Postop neuroimaging findings	Management	Remained deficit
Bloomfield and Sonntag ¹⁶ (1985)	Right MCA bifurcation	7	ND	Left hemiparesis	9		Dexamethasone	Left hemiparesis
Gutiérrez ¹¹ (2001)	Left ophthalmic	5	ND	Aphasia, right hemiparesis	1		Intraarterial papaverine	Right hemiparesis
Kitazawa ¹² (2005)	Left paraclinoid	4	ND	Aphasia	12		Intraarterial angioplasty, triple H	None
Kitazawa ¹² (2005)	Left paraclinoid	4	ND	Aphasia, right hemiparesis	9	SAH	Triple H	None
Kitazawa ¹² (2005)	Left paraclinoid	5	ND	Left hemiparesis	5	Small EDH	Intraarterial papaverine, triple H	None
Paolini ⁸ (2005)	Right MCA bifurcation	8	ND	Aphasia, right hemiparesis	28	Small ICH	Hydration antithrombotics	None
Yang ¹⁸ (2015)	Left ICA terminal	5	ND	Aphasia	28		Hydration antithrombotics	Dysphasia
Yang ¹⁸ (2015)	Left MCA bifurcation	6	ND	Aphasia	10		Intraarterial papaverine, hydration antithrombotics	Dysphasia
Tsyben ¹³ (2016)	Left MCA	5	ND	Right hemiparesis	2		Intraarterial verapamil	Dysphasia
Tsyben ¹³ (2016)	AcomA, left MCA		ND	Right hemiparesis	2		Intraarterial verapamil, nimodipine	None
Hashimoto ¹⁵ (2016)	Left PcomA	5	Moderate headache	Aphasia, right hemiparesis	11		Hypervolemia, antithrombotics	Acalculia, paraphasia
Campe ⁷ (2019)	Right MCA bifurcation		ND	Left hemiparesis	12		Oral nimodipine, antithrombotics	None
Cuoco ¹⁹ (2020)	Left MCA bifurcation	5	ND	Right hemiparesis	13,26		Intraarterial nimodipine	Right hemiparesis
Ceraudo ¹⁷ (2020)	Left MCA bifurcation	5	ND	Aphasia, right hemiparesis	6		Intraarterial nimodipine	Dysphasia
Knight ²⁰ (2020)	AcomA	5	ND	Aphasia	5		Intraarterial nicardipine, triple H	Short-term memory deficit
Vachata ¹⁰ (2020)	Left MCA	10	ND	Aphasia	5		Triple H, milrinon, nimodipine	None
Vachata ¹⁰ (2020)	Left MCA	7	ND	Aphasia	6		Triple H, milrinon, nimodipine	Fatigue, depression deterioration
Kim ¹⁴ (2020)	AcomA	5	ND	Motor dysphasia	14		Intraarterial nimodipine	None
Kim ¹⁴ (2020)	Left PcomA		ND	Motor dysphasia, right hemiparesis	12		Intraarterial nimodipine	None
Peterson ⁹ (2020)	Right MCA bifurcation	8	ND	Left hemiparesis	29		Intraarterial verapamil, triple H, aspirin	Left hemiparesis
Present study	Left MCA bifurcation	3.7	Severe headache	Aphasia, right hemiparesis	7	Minimal EDH	Intraarterial nimodipine	Dysphasia

postop, postoperative; POD, postoperative day; MCA, middle cerebral artery; ND, no described; ICA, internal carotid artery; Triple H, hypertension, hypervolemia, and hemodilution; SAH, subarachnoid hemorrhage; EDH, epidural hemorrhage; ICH, intracerebral hemorrhage; AcomA, anterior communicating artery; PcomA, posterior communicating artery.

solved without any complications.²⁴ Thus, most of the case reports did not emphasize symptoms of vasospasm before ischemic events. However, even though severe vasospasm rarely occurs in the neurosurgical field, severe vasospasm must be suspected in patients with sustained, intractable headaches after clipping surgery. We analyzed 17 cases that reported ischemic events associated with vasospasm that occurred after UIA clipping surgery (Table 1). Fourteen of the 17 cases were females, and most were middle-aged females (40–60 y). Postoperative pain was found to be more common in females, who had higher pain scores.²⁵ Females with SAH have a higher risk of radiographic vasospasm, clinical deterioration, and cerebral infarction.²⁶ Interestingly, most patients who experienced ischemic events after elective clipping surgery were middle-aged females.¹⁴ Thus, assessing whether other sex-specific factors could contribute to these findings should be highlighted.

Nevertheless, there is no standard protocol for management. Previous studies have reported successful treatments with nimodipine or verapamil, mostly with favorable outcomes after managing the spasm.^{7–20}

In conclusion, sustained intractable headaches after UIA treatment can be a severe premonitory sign of cerebral vasospasm. Although outcomes are favorable, the consequences can include a risk of permanent neurologic deficit. Early awareness and proper management can prevent undesirable results.

Fund

None.

Ethics Statement

Ethical approval was granted in accordance with national requirements, and the need for written informed consent was waived (Institutional Review Board of Jeju National University Hospital). We anonymized patient information, such as sex and age, in the case section to prevent the identification of individuals.

Conflicts of Interest

YS has been the assistant editor of *Neurointervention* since 2018. However, he/she has not been involved in the peer reviewer selection, evaluation, or decision process of this article. No potential conflict of interest relevant to this article was reported. No other authors have any conflicts of interest to disclose.

Author Contributions

Concept and design: JGK, YS, and JKR. Analysis and interpretation: JGK, JJS, and CHK. Data collection: JGK, YS, and JJS. Writing the article: JGK. Critical revision of the article: JKR. Final approval of the article: JKR. Overall responsibility: JKR.

ORCID

Joong-Goo Kim: <https://orcid.org/0000-0002-4166-6023>

Chul-Hoo Kang: <https://orcid.org/0000-0002-4176-0941>

Jae Jon Sheen: <https://orcid.org/0000-0002-0474-5830>

Yunsun Song: <https://orcid.org/0000-0003-4738-0533>

Jong-Kook Rhim: <https://orcid.org/0000-0003-2538-8374>

REFERENCES

1. Laukka D, Kivelev J, Rahi M, Vahlberg T, Paturi J, Rinne J, et al. Detection rates and trends of asymptomatic unruptured intracranial aneurysms from 2005 to 2019. *Neurosurgery* 2024;94:297-306
2. Vlaskin MH, Algra A, Brandenburg R, Rinkel GJ. Prevalence of unruptured intracranial aneurysms, with emphasis on sex, age, comorbidity, country, and time period: a systematic review and meta-analysis. *Lancet Neurol* 2011;10:626-636
3. Fu AY, Kumarapuram S, Sreenivasan S, Roychowdhury S, Gupta G. Trends in global research for treating intracranial aneurysms: a bibliometric analysis. *World Neurosurg* 2023;177:143-151.e4
4. Scullen T, Mathkour M, Nerva JD, Dumont AS, Amenta PS. Editorial. Clipping versus coiling for the treatment of middle cerebral artery aneurysms: which modality should be considered first? *J Neurosurg* 2019;133:1120-1123
5. Pflaeging M, Kabbasch C, Schlamann M, Pennig L, Juenger ST, Grunz JP, et al. Microsurgical clipping versus advanced endovascular treatment of unruptured middle cerebral artery bifurcation aneurysms after a "coil-first" policy. *World Neurosurg* 2021;149:e336-e344
6. Lee SH, Lee SU, Kwon OK, Bang JS, Ban SP, Kim T, et al. Clinical outcomes of clipping and coiling in elderly patients with unruptured cerebral aneurysms: a national cohort study in Korea. *J Korean Med Sci* 2021;36:e178
7. Campe C, Neumann J, Sandalcioglu IE, Rashidi A, Luchtmann M. Vasospasm and delayed cerebral ischemia after uneventful clipping of an unruptured intracranial aneurysm - a case report. *BMC Neurol* 2019;19:226
8. Paolini S, Kanaan Y, Wagenbach A, Fraser K, Lanzino G. Cerebral vasospasm in patients with unruptured intracranial aneurysms.

- Acta Neurochir (Wien)* 2005;147:1181-1188; discussion 1188
9. Peterson CM, Podila SS, Girotra T. Unruptured aneurysmal clipping complicated by delayed and refractory vasospasm: case report. *BMC Neurol* 2020;20:344
 10. Vachata P, Lodin J, Hejčl A, Cihlář F, Sameš M. Delayed ischemic neurological deficit after uneventful elective clipping of unruptured intracranial aneurysms. *Brain Sci* 2020;10:495
 11. Gutiérrez O, Caldas JG, Rabello JP. Unruptured aneurysm: vasospasm after surgery and endovascular treatment. A case report. *Interv Neuroradiol* 2001;7:37-39
 12. Kitazawa K, Hongo K, Tanaka Y, Oikawa S, Kyoshima K, Kobayashi S. Postoperative vasospasm of unruptured paraclinoid carotid aneurysms: analysis of 30 cases. *J Clin Neurosci* 2005;12:150-155
 13. Tsyben A, Paldor I, Laidlaw J. Cerebral vasospasm and delayed ischaemic deficit following elective aneurysm clipping. *J Clin Neurosci* 2016;34:33-38
 14. Kim M, Son W, Kang DH, Park J. Cerebral vasospasm with delayed ischemic neurologic deficit after unruptured aneurysm surgery: report of two cases and review of the literature. *J Korean Neurosurg Soc* 2021;64:665-670
 15. Hashimoto H, Kameda M, Yasuhara T, Date I. A case of unexpected symptomatic vasospasm after clipping surgery for an unruptured intracranial aneurysm. *J Stroke Cerebrovasc Dis* 2016;25:e25-e27
 16. Bloomfield SM, Sonntag VK. Delayed cerebral vasospasm after uncomplicated operation on an unruptured aneurysm: case report. *Neurosurgery* 1985;17:792-796
 17. Ceraudo M, Truffelli M, Anania P, Prior A, D'Andrea A, Zona G, et al. A case report of cerebral vasospasm following elective clipping of unruptured aneurysm: pathogenetic theories and clinical features of a dangerous underestimated event. *Surg Case Rep* 2020;3:1-6
 18. Yang K, Ahn JS, Park JC, Kwon DH, Kwun BD. Clinical and angiographical delayed cerebral vasospasms after uncomplicated surgical clipping of unruptured intracranial aneurysms: illustrated review and two case reports. *Turk Neurosurg* 2015;25:662-665
 19. Cuoco JA, Williams EL, Rogers CM, Patel BM, Marvin EA. Recurrent cerebral vasospasm and delayed cerebral ischemia weeks subsequent to elective clipping of an unruptured middle cerebral artery aneurysm. *World Neurosurg* 2020;141:52-58
 20. Knight JA 2nd, Bigder MG, Mandel M, Li Y, Steinberg GK. Contralateral vasospasm in an uncomplicated elective anterior communicating artery aneurysm clipping. *World Neurosurg* 2020;138:214-217
 21. Hansen-Schwartz J. Cerebral vasospasm: a consideration of the various cellular mechanisms involved in the pathophysiology. *Neurocrit Care* 2004;1:235-246
 22. Cook DA. Mechanisms of cerebral vasospasm in subarachnoid haemorrhage. *Pharmacol Ther* 1995;66:259-284
 23. Witten AJ, Ordaz JD, Alentado VJ, Bohnstedt B. Intracranial vasospasm after evacuation of acute spontaneous subdural hematoma. *Cureus* 2021;13:e15284
 24. Rocha-Filho PA, Gherpelli JL, de Siqueira JT, Rabello GD. Post-craniotomy headache: characteristics, behaviour and effect on quality of life in patients operated for treatment of supratentorial intracranial aneurysms. *Cephalalgia* 2008;28:41-48
 25. Chowdhury T, Garg R, Sheshadri V, Venkatraghavan L, Bergese SD, Cappellani RB, et al. Perioperative factors contributing the post-craniotomy pain: a synthesis of concepts. *Front Med (Lausanne)* 2017;4:23
 26. Lai PMR, Gormley WB, Patel N, Frerichs KU, Aziz-Sultan MA, Du R. Age-dependent radiographic vasospasm and delayed cerebral ischemia in women after aneurysmal subarachnoid hemorrhage. *World Neurosurg* 2019;130:e230-e235