



Successful Embolization of a Direct Carotid Cavernous Fistula under Gadolinium-Based Angiography

Yan-Lin Li, EBIR, FRCR, Sandhya Rai, BSc, Peter John Cox, DPhil, FRCR

Department of Neuroradiology, John Radcliffe Hospital, Oxford University Hospitals NHS Foundation Trust, Oxford, UK

Endovascular neurointervention is typically performed with iodinated contrast medium (ICM) under fluoroscopy. However, some patients may be contraindicated to such procedures based on their sensitivity to ICM. In this report, we describe a case of successful coil embolization of a direct carotid cavernous fistula using angiography with gadolinium-based contrast agents in a patient with severe allergic reaction to ICM. The clinical decision-making for this patient was further complicated by comorbidities of renal impairment, drug allergies, and previously severe gastrointestinal bleeding.

Key Words: Gadolinium; Carotid cavernous fistula; Aneurysm

Correspondence to:

Peter John Cox, DPhil, FRCR

Department of Neuroradiology, John Radcliffe Hospital, Oxford University Hospitals NHS Foundation Trust, Oxford OX39DU, UK

Tel: +44-75-4118-8720

E-mail: peter.cox@ouh.nhs.uk

Received: May 16, 2024

Revised: May 27, 2024

Accepted: May 31, 2024

CASE REPORT

An elderly patient presented with acute reduced right visual acuity, right 3rd nerve palsy, headache, and vomiting. She had a history of a 5 mm right cavernous internal carotid artery (ICA) aneurysm discovered during investigation for headache 6 years prior, managed with serial imaging (Fig. 1A).

Her medical history was also remarkable for previous severe gastrointestinal bleeding and multiple drug allergies, including to proton pump inhibitors and iodinated contrast mediums (ICMs). Her previous allergic reactions to ICM included urticaria responsive to steroids and an episode of cardiac arrest after administration of 75 mL iopamidol (Niopam-370; Bracco Ltd.) for computed tomography (CT) angiography. The

patient also had mild renal impairment (stage 2 chronic kidney disease) with an estimated glomerular filtration rate (EGFR) of 78 mL/min/1.73 m².

Magnetic resonance (MR) time-resolved angiography of the brain showed a carotid cavernous fistula (CCF) secondary to rupture of the known medial pointing cavernous ICA sidewall (likely superior hypophyseal artery) aneurysm decompressing into the cavernous sinus, petrosal sinuses, and pterygoid venous plexus. There was no reflux to the superior ophthalmic veins nor cortical venous reflux. There was no intracranial hemorrhage (Fig. 1B).

Multidisciplinary discussion involving neurointerventional radiology, neurosurgery, immunology, and pharmacy was conducted, with consensus to offer endovascular intervention in the first in-

Copyright © 2024 Korean Society of Interventional Neuroradiology

This is an Open Access article distributed under the terms of the Creative Commons Attribution Non-Commercial License (<http://creativecommons.org/licenses/by-nc/4.0>) which permits unrestricted non-commercial use, distribution, and reproduction in any medium, provided the original work is properly cited.

pISSN 2093-9043
eISSN 2233-6273

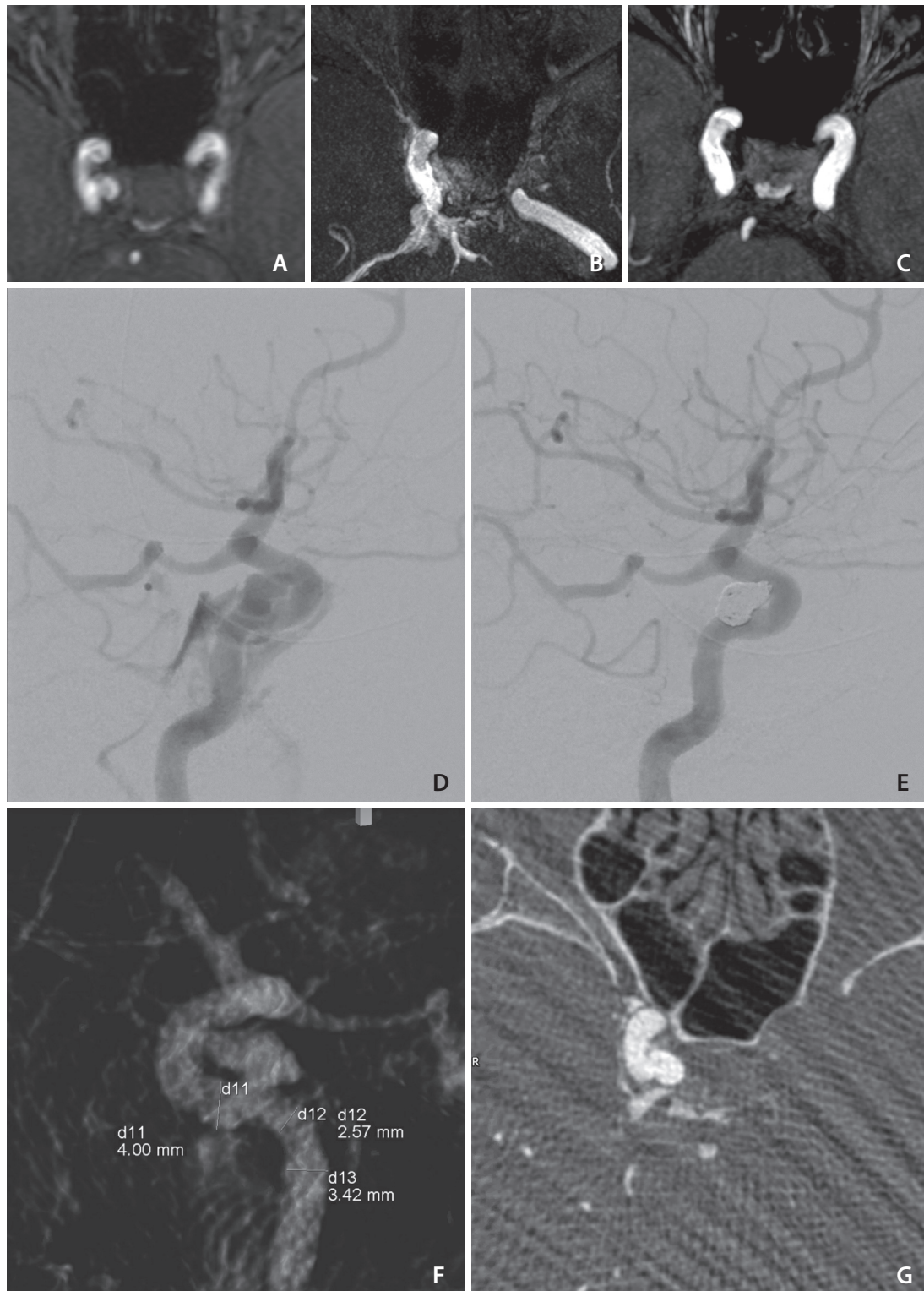


Fig. 1. Magnetic resonance angiography (MRA) axial images showing previously unruptured right cavernous internal carotid artery aneurysm 6 years prior in time-of-flight sequence (A), evidence of rupture into the cavernous sinus in the present admission in time-resolved imaging of contrast kinetics sequence (B), and complete occlusion on control MRA in 6 months post embolization (C). Image quality of gadolinium enhanced digital subtraction angiography images in lateral projection on pre-procedural (D) and post-coiling injections (E). Image quality of gadolinium enhanced three-dimensional rotational (F) and axial reformatted (G) images in cone-beam computed tomography acquisition used for working projection curation and procedure planning.

stance using gadolinium-based contrast agent (GBCA) as the intraprocedural contrast agent. This use received exceptional approval by the institutional medicines and therapeutics committee.

Procedure

The procedure was performed under general anesthesia. No premedication with steroid or other anti-allergic medications was given as the patient previously tolerated GBCA administration. A 6 Fr guide-catheter was introduced transfemorally and parked in the right distal ICA. A conventional biplane and three-dimensional (3D) rotational angiogram was obtained for procedure planning using a neuroangiography protocol of an Artis Q biplane angiography machine (Siemens Healthineers). A microcatheter (SL-10; Stryker) was navigated into the aneurysm. A dual-lumen balloon (Eclipse 2L, 6x20 mm; Balt Extrusion) was then deployed across the neck of the aneurysm (jailing technique). Seven detachable coils were deployed resulting in complete occlusion of the fistula (Fig. 1D–G).

The patient tolerated the procedure well with no evidence of anaphylactoid reaction, nephrogenic systemic fibrosis, or contrast induced nephropathy. No significant change in her renal function was observed. Her serum creatinine on the day before and after the procedure were 68 $\mu\text{mol/L}$ and 66 $\mu\text{mol/L}$, respectively (normal range: 49–90 $\mu\text{mol/L}$). Her EGFR before and after the procedure were 78 mL/min/1.73 m^2 and 81 mL/min/1.73 m^2 , respectively (normal range: >90 mL/min/1.73 m^2). Her neurological deficits improved following the embolization procedure. MR angiography 6 months post embolization demonstrated enduring occlusion of the fistula (Fig. 1C).

Gadoteridol (ProHance; Bracco Ltd.) was used in the procedure. A total volume of 45 mL dilute contrast solution was injected intra-arterially. This contrast constituted of 72% ProHance (32.4 mL) and 28% 0.9% sodium chloride solution (12.6 mL). This was equivalent to 5 hand injections for fluoroscopic runs (around 6 mL each) and 1 injection for 3D rotational angiography (around 15 mL). The patient weight was 53.3 kg.

DISCUSSION

Management of Patients with Allergic Reaction to Iodinated Contrast Medium

Allergic reactions to ICM are common and affect up to 3%

of the population depending on definition. Intravenous corticosteroids (typically methylprednisolone 40 mg or hydrocortisone 200 mg IV) given 4–5 hours prior to injection have been proven to reduce the incidence and severity of these allergic reactions.¹

In patients with an undifferentiated type of contrast reaction, changing from a high-osmolar, ionic ICM to a low-osmolar, non-ionic ICM or changing from one to another low-osmolar ICM, have been recommended to reduce the likelihood of a subsequent contrast reaction.²

There is a paucity of high-level evidence on patients with severe allergic reactions given its the low incidence (0.06%). It may be sensible to consider alternative contrast agents with a different chemical structure such as carbon dioxide and GBCAs. In neurointervention, carbon dioxide is contraindicated due to risk of cerebral ischemia. Therefore, GBCAs are the only alternative for these patients at present, as they have no cross reactivity with ICM.

Gadolinium-Based Contrast Agent in Catheter-Directed Angiography

GBCAs are widely adopted as a contrast agent in MR imaging for their paramagnetic properties. Gadolinium is also a heavy metal element that attenuates photons. Gadolinium has a higher K-edge (50.2 keV) than iodine (33 keV), which favors imaging at higher kilovoltages (77–96 kVp) than ICM-enhanced imaging (63–73 kVp).

Currently, there are no GBCAs designed or recommended for catheter-directed arteriography. However, it has been adopted on an exceptional basis for interventions in various body organs, such as coronary,³ visceral, extremity, and biliary.⁴ Interventions that require high-volume contrast use (e.g., aortic interventions) may not be suitable. GBCAs are also increasingly used in dual energy and spectral CT.⁵

In neurointervention, there are a small number of reports on using GBCA in diagnostic angiograms,⁶ carotid stenting⁷ and stroke thrombectomy.⁸ To our knowledge, this is the first report in the literature on using GBCA to embolize an arteriovenous fistula, which are typically high-flow and relatively complex lesions requiring larger volumes of contrast administration.

Contrast Safety

GBCAs have a plasma half-life of about 2 hours and are nearly 100% cleared from the blood stream within 24 hours. The shift from linear group 1 to macrocyclic group 2 agents also

have greatly reduced the risk of nephrogenic systemic fibrosis, even in patients with advanced renal failure.⁹

ProHance is a group 2 agent with an excellent safety profile, and therefore was chosen for our intervention. Each mL of ProHance contains 279.3 mg gadoteridol, 0.23 mg calcein calcium, 1.21 mg tromethamine, and water for injection. In adults with normal renal function undergoing contrast enhanced MR imaging, a typical dose of 0.1 mmol/kg (0.2 mL/kg) is recommended. In suboptimal studies, a supplementary dose of 0.2 mmol/kg (0.4 mL/kg) 30 minutes after initial injection is recommended. Therefore, the dose limit is 0.3 mmol/kg (0.6 mL/kg).¹⁰

The clinical consequences of overdose have not been reported. Naturally, the clinical concerns would be increased risk for nephrogenic systemic fibrosis or central nervous system deposition, of which long term effects remain unknown.

In an “average” patient weighting 50–75 kg, this translates into 30–45 mL volume of undiluted contrast for use. Prior to our intervention, we tested the visibility of contrast *ex vivo* in our angi suite and determined that around 70% concentration would permit satisfactory image quality for the complexity of our intervention. This is likely to vary depending on machine, patient, and disease factors.

Careful individual consideration should be made prior to undertaking neurointervention using GBCA. Given the paucity of clinical data, the patient must be fully informed of the potential risks, benefits, and alternatives. Discussion should also be made regarding potential use of ICM in case of need. Once the decision to treat is made, strategies can be implemented to minimize the contrast dose to maximize safety.

Presently, for patients with grade 2 and grade 3 chronic kidney disease (EGFR >30 mL/min/1.73 m²), no additional consideration or precautions are necessary. For patients with grade 4 and grade 5, guidelines recommend individual consideration and usage of newer GBCA agents, and counseling patients at low risk (<1%) of developing nephrogenic systemic fibrosis.¹¹

In addition, measures should be taken to optimize renal function, such as hydration and renal replacement therapy. Preprocedural cross-sectional imaging should be obtained to understand angioanatomy and minimize the need of contrast in navigation. In complex dynamic pathology, it may be sensible to perform a diagnostic angiogram in the first instance, followed by second stage intervention. The treatment approach may have to be modified based on contrast

concerns and other patient needs. In our patient, placing a flow diverting stent would require the least amount of contrast. However, as the patient had previous severe gastrointestinal bleeding and allergy to proton pump inhibitors, it would not be safe to load her with double antiplatelet therapy. A transvenous embolization approach would probably require a significantly higher contrast load and was considered less favorable.

CONCLUSION

We report the first in literature case of CCF embolization using GBCA as a contrast agent for angiography. The challenges in technique and decision-making in managing these patients were illustrated. A good understanding of contrast properties and a sensible appreciation of risks and benefits are crucial in ensuring best patient outcomes.

Fund

None.

Ethics Statement

Informed consent is obtained from the patient for research publication. Institutional Review Board approval is waived for the use of anonymized patient data for retrospective clinical case report.

Conflicts of Interest

The authors have no conflicts to disclose.

Author Contributions

Concept and design: YLL and PJC. Analysis and interpretation: YLL. Data collection: YLL, SR, and PJC. Writing the article: YLL. Critical revision of the article: YLL, SR, and PJC. Final approval of the article: PJC. Overall responsibility: PJC.

ORCID

Yan-Lin Li: <https://orcid.org/0000-0002-1722-4188>

Sandhya Rai: <https://orcid.org/0009-0001-9367-6733>

Peter John Cox: <https://orcid.org/0000-0002-0884-0608>

REFERENCES

1. American College of Radiology (ACR). ACR manual on contrast

- media. *ACR*; 2023
2. Abe S, Fukuda H, Tobe K, Ibukuro K. Protective effect against repeat adverse reactions to iodinated contrast medium: pre-medication vs. changing the contrast medium. *Eur Radiol* 2016;26:2148-2154
 3. Saleh L, Juneman E, Movahed MR. The use of gadolinium in patients with contrast allergy or renal failure requiring coronary angiography, coronary intervention, or vascular procedure. *Catheter Cardiovasc Interv* 2011;78:747-754
 4. Spinosa DJ, Angle JF, Hartwell GD, Hagspiel KD, Leung DA, Matsumoto AH. Gadolinium-based contrast agents in angiography and interventional radiology. *Radiol Clin North Am* 2002;40:693-710
 5. Thomas JV, Bolus DN, Jackson BE, Berland LL, Yester M, Morgan DE. Gadoxetate disodium enhanced spectral dual-energy CT for evaluation of cholangiocarcinoma: preliminary data. *Ann Med Surg (Lond)* 2016;6:17-22
 6. Sakamoto S, Eguchi K, Shibukawa M, Kiura Y, Yamasaki F, Kajiwara Y, et al. Cerebral angiography using gadolinium as an alternative contrast medium in a patient with severe allergy to iodinated contrast medium. *Hiroshima J Med Sci* 2010;59:15-16
 7. Amar AP, Larsen DW, Teitelbaum GP. Percutaneous carotid angioplasty and stenting with the use of gadolinium in lieu of iodinated contrast medium: technical case report and review of the literature. *Neurosurgery* 2001;49:1262-1265; discussion 1265-1266
 8. de Albóniga-Chindurza A, Ortega-Quintanilla J, Alcalde-López J, Zapata-Arriaza E, González A. Intra-arterial gadolinium as an alternative to iodinated contrast agent in thrombectomy. *Neurologia (Engl Ed)* 2020;35:681-683
 9. Woolen SA, Shankar PR, Gagnier JJ, MacEachern MP, Singer L, Davenport MS. Risk of nephrogenic systemic fibrosis in patients with stage 4 or 5 chronic kidney disease receiving a group II gadolinium-based contrast agent: a systematic review and meta-analysis. *JAMA Intern Med* 2020;180:223-230
 10. Bracco Diagnostics Inc. ProHance® [Internet]. Bracco Diagnostics Inc.; 2017 Sep [cited 2024 May 16]. Available from: https://www.accessdata.fda.gov/drugsatfda_docs/label/2017/020131s0271-bl.pdf
 11. Schieda N, Blaichman JI, Costa AF, Glikstein R, Hurrell C, James M, et al. Gadolinium-based contrast agents in kidney disease: a comprehensive review and clinical practice guideline issued by the Canadian Association of Radiologists. *Can J Kidney Health Dis* 2018;5:2054358118778573