

# Endovascular Management of the Wide-neck Aneurysms: the Applications of the Coils and Catheter

Chang-Woo Ryu, MD<sup>1</sup>, Jun-Seok Koh, MD<sup>2</sup>, Cheol Young Lee, MD<sup>2</sup>, Eui-Jong Kim, MD<sup>3</sup>

The endovascular treatment of aneurysms with wide-neck or the incorporated branch can be technically very challenging. Various neck protecting devices, such as temporary balloons or self-expanding stents are effective for management of the wide-neck aneurysm. However, these devices are not amenable to successful management of aneurysms with unfavorable configurations, because the introduction of additional devices into small intracranial vessels is technically demanding. Without the support of these neck protecting devices, the use of three-dimensional (3D) coils or coil delivery technique with the application of microcatheter can help to overcome the unfavorable configuration of the aneurysm. This article presents 3D coils, double catheter method, and catheter-assisted method for coil embolization of the wide-neck aneurysm independently with neck protecting device. These methods are considered as viable alternatives for management of wide-neck aneurysms. To make the strategy of the endovascular treatment of the wide-neck aneurysm, neurointerventionists should consider the aneurysm configuration, relationship between the aneurysm and parent artery, the presence of incorporated branch, proximal approach route, technical availability, the risk of thromboembolic complications, and antiplatelet therapy.

**Key Words :** Aneurysm; Endovascular therapy; Microcatheter; Coil

Endovascular coil embolization of intracranial aneurysms has become an accepted treatment option worldwide (1). However, principal disadvantage of embolization of aneurysms with detachable coils is that embolization could be limited by unfavorable shape of the aneurysms (2–5). Coils packed into the lumen of the wide-neck aneurysms have the inherent difficulty

that coils can herniate into the parent vessels. The wide-neck of aneurysms also usually result in incomplete occlusion and correlate with a higher recanalization rate than the corresponding rates for small-necked aneurysms (2, 3). Therefore, the endovascular treatment of wide-neck aneurysms can be technically very challenging. Other unfavorable aneurysm configuration, major branches incorporating with the aneurysm fundus, is the main technical limitations, because this configuration may result in the thromboembolic complication during coil embolization of aneurysms.

Although these geometric factor limiting endovascular coil embolization of intracranial aneurysms, technical advance permit successful embolization of the aneurysms that cannot be treated otherwise. Various neck protecting devices, such as temporary balloons or self-expanding stents can increase the rate of successful

Departments of <sup>1</sup>Radiology and <sup>2</sup>Neurosurgery, Gangdong KyungHee University Hospital, Seoul, Korea; <sup>3</sup>Department of Radiology, KyungHee University Medical Center, Seoul, Korea

Received May 23, 2010;

accepted after revision July 25, 2010.

**Correspondence to:** Chang-Woo Ryu, MD, Department of Radiology, Gangdong KyungHee University Hospital, School of Medicine, Kyunghee University, 149 Sangil-dong, Gangdong-gu, Seoul 137-727, Korea.

Tel. 82-2-440-6186 Fax. 82-2-440-6932

E-mail: md.cwryu@gmail.com

**Neurointervention 2010;5:71-78**

embolization (5–8). However, the introduction of additional devices into small intracranial vessels is technically demanding and the geometric configuration of the aneurysm does not allow the routine application of these techniques. These techniques also may not be effective for aneurysm with a branch incorporated into the sac. Another disadvantage is the increase of the cost associated with an additional device.

Without the support of these neck protecting devices, the use of three-dimensional (3D) coils or coil delivery technique with the application of microcatheter can help to overcome the unfavorable configuration of the aneurysm. This article presents the role of the 3D coils and various catheter techniques for coil embolization of the wide-neck aneurysm independently with neck protecting device.

### THREE-DIMENSIONAL COILS

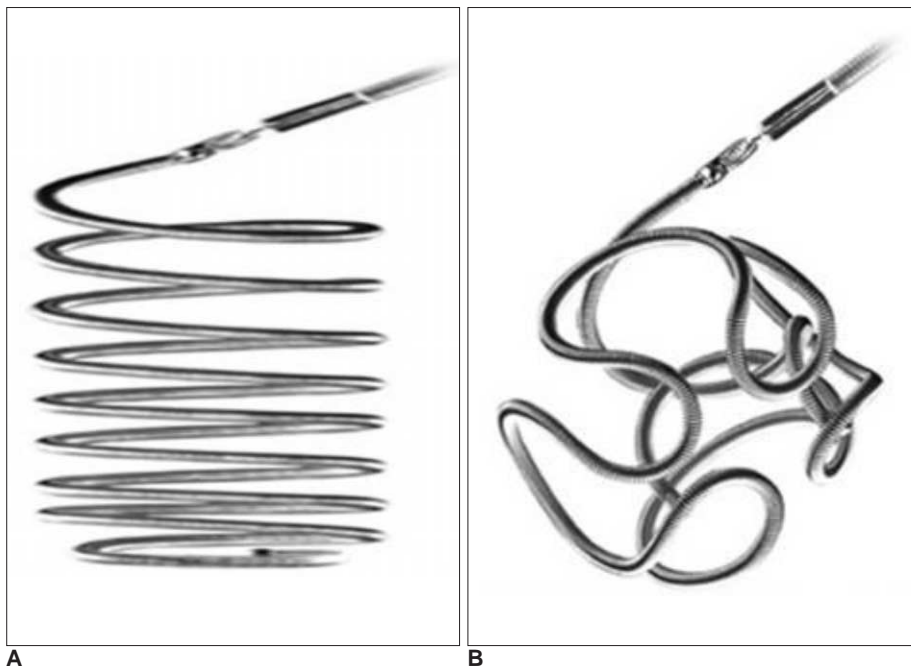
The Use of 3D shaped detachable coils enables the treatment of intracranial aneurysms with an unfavorable geometry, which would otherwise not be amenable to endovascular treatment without adjunctive techniques (9–11). In nascent stage of coil embolization, detachable coil had only a helical configuration and relied on a rather random combination of forces to generate a complex configuration with loops extending across the aneurysm neck (Fig. 1). Therefore, the first coil should be repeatedly pushed and pulled to achieve the favorable basket. The advantage of the 3D coil is that the coil has a complex shape with loops extending

across the aneurysm neck because of its shape memory for a complex sphere.

The 3D coil is used as a first coil in the embolization of cerebral aneurysms in an attempt to form a basket, with coil loops bridging the aneurysm neck. It allows the complete treatment of some wide-necked aneurysms without the need for neck remodeling techniques. The benefit of 3D coil is not only the production of the stable coil frame but only the concentric filling which leads to better packing densities and creating a more stable filling of the aneurysm (11).

Complex fill coils that had developed after 3D coil have a propensity to form a 3D cage after deployment, and their comfortability is superior to that of 3D coils with subsequently less compartmentalization, allowing more homogeneous filling of irregular shaped aneurysm. Helical coils, however, are less stiff than 3D coils and may allow packing the small space. Therefore, helical coils more suitable to use for finishing coils or to fill the residual small lumen.

Several reports presented that the use of 3D coils could facilitate the treatment of wide-neck aneurysm not amenable to treatment with conventional helical coils and were useful for improving initial coil packing density (9–14). As these advantages of 3D coils, almost vendors have been producing not only helical filling coils but only 3D coils. Various coil loop designs are being researched for better comfortability without losing the robust 3D characteristics.



**Fig. 1. A, B.** Configurations of helical and three-dimensional coil.

**A.** GDC® standard (Boston Scientific Corporation, Natick, MA, USA).

**B.** GDC® 3-Dimensional (3D) Shape (Boston Scientific Corporation, Natick, MA, USA).

## DOUBLE CATHETER METHOD

Following the use of double catheters for the wide-necked intracranial aneurysm embolization by Baxter et al. (15), various authors have reported using technically modified double catheter method (16–21). One concern with placing coils in wide-neck aneurysms is that, even if the initial coil can be placed to achieve a basket, subsequent coils may displace the detached initial coil through the wide-neck into the parent vessel. A solution to this problem is to place two coils into the aneurysm prior to detaching either coil. The key concept of this technique is that coils simultaneously into the aneurysm would cause the coils to intermingle with each with the other and remain within the aneurysm (Fig. 2).

Technical benefit of this method is that first coil

remains retrievable if the second coil should displace the first. Additionally, the bracing characteristic of two coils results in a more stable mesh configuration prior to placement of additional coils.

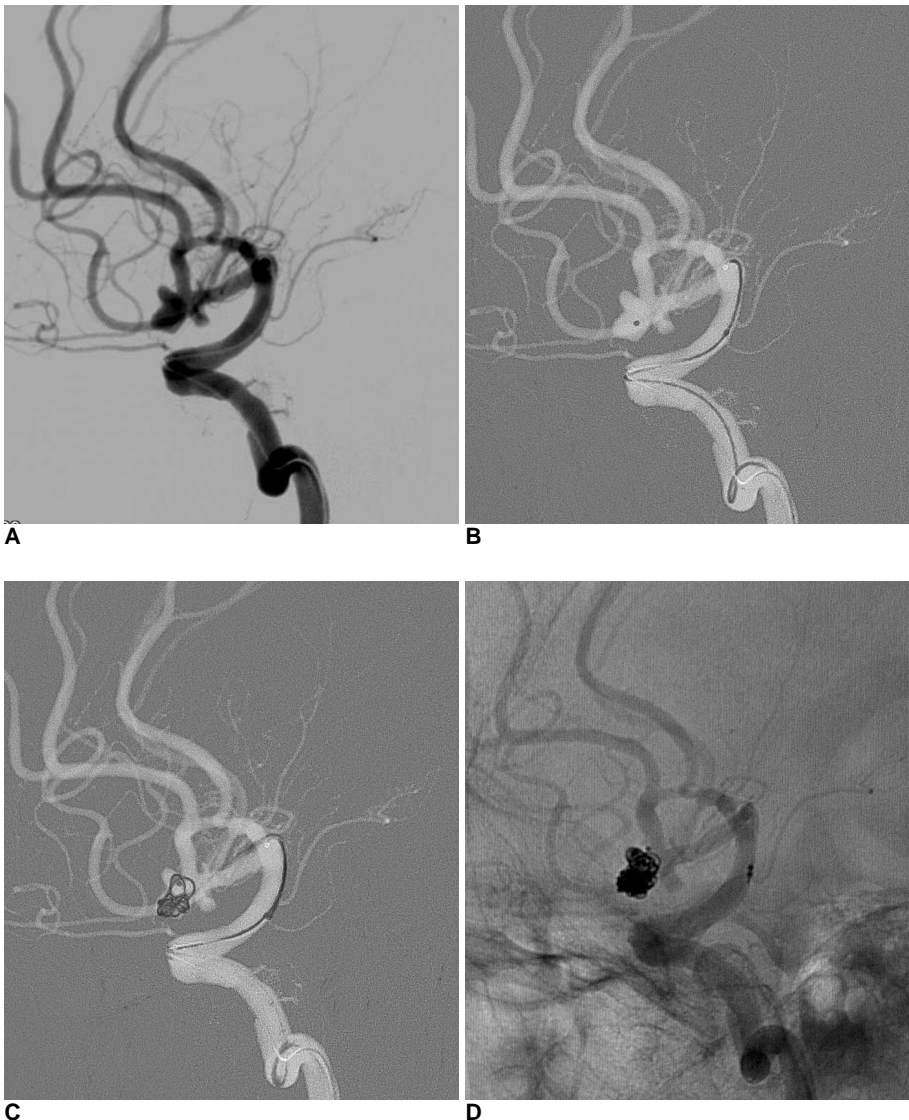
The neurointerventionist should consider the following issues when using double catheter method:

### 1. Guiding Catheter

The internal diameter of 6Fr guiding catheter is enough to pass the two 0.010 inch microcatheters. If two guiding catheters are being used, placement of one catheter in the internal carotid artery and the other in the common carotid artery should be considered.

### 2. Microcatheters

In practice, it is important to distinguish between the two microcatheters in fluoroscopic views during the



**Fig. 2.** A 71-year-old man with subarachnoid hemorrhage.

**A.** Lateral view of left carotid artery angiogram show multilobulated aneurysm of anterior communicating artery. This aneurysm has the wide-neck and is compartmentalized into superior and inferior fundus.

**B.** First microcatheter is positioned within inferior fundus of the aneurysm.

**C.** 3D coil is deployed through the first catheter, and keeps within the inferior fundus of the aneurysm. Then, the second microcatheter is placed within superior fundus of the aneurysm.

**D.** Angiogram obtained immediately after embolization shows compact occlusion of the aneurysmal sac.

procedures. Therefore, a use of microcatheters with different-shaped distal markers can help to distinguish each other.

The aneurysm is sequentially catheterized with two microcatheters. In general, the aneurysm sac was divided into two imaginary parts, and each part was occupied by the first and second coils. These imaginary parts need not be half of the aneurysm. According to the shape of the aneurysm, two imaginary parts can be divided into the inflow and outflow zone, or the superficial and deep part, or each different sac in multilobulated aneurysm (Fig. 3). This compartmentalization is effective in filling stage as well as framing stage.

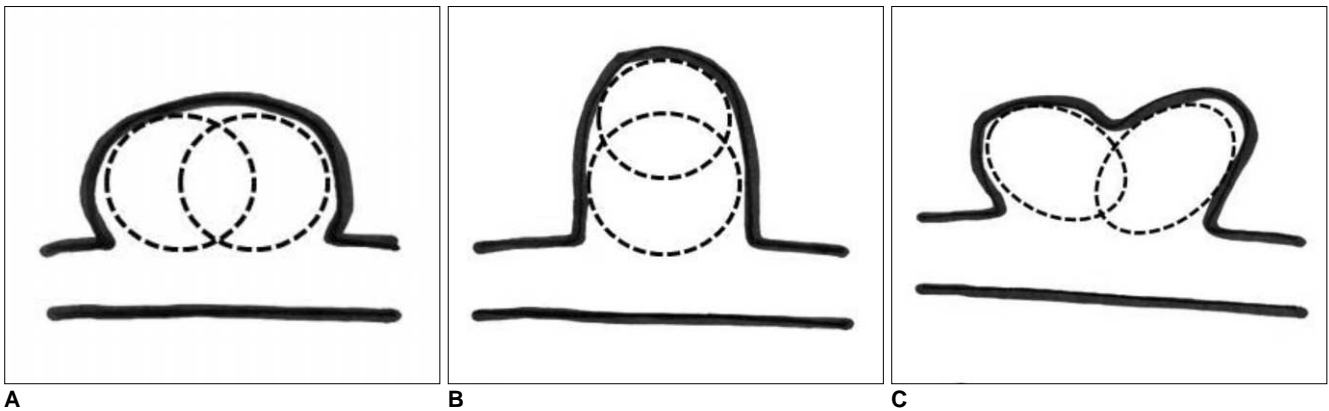
### 3. Coils

Coil size (diameter) is selected according to the sizes

of these imaginary parts. The use of two 3D or complex shaped coils at the start of the procedure has the greatest likelihood of forming a stable mass that resists herniation into the parent vessels during subsequent coil packing. Coils are introduced into the aneurysm using either simultaneous insertion through each catheter or sequential insertion through each catheter.

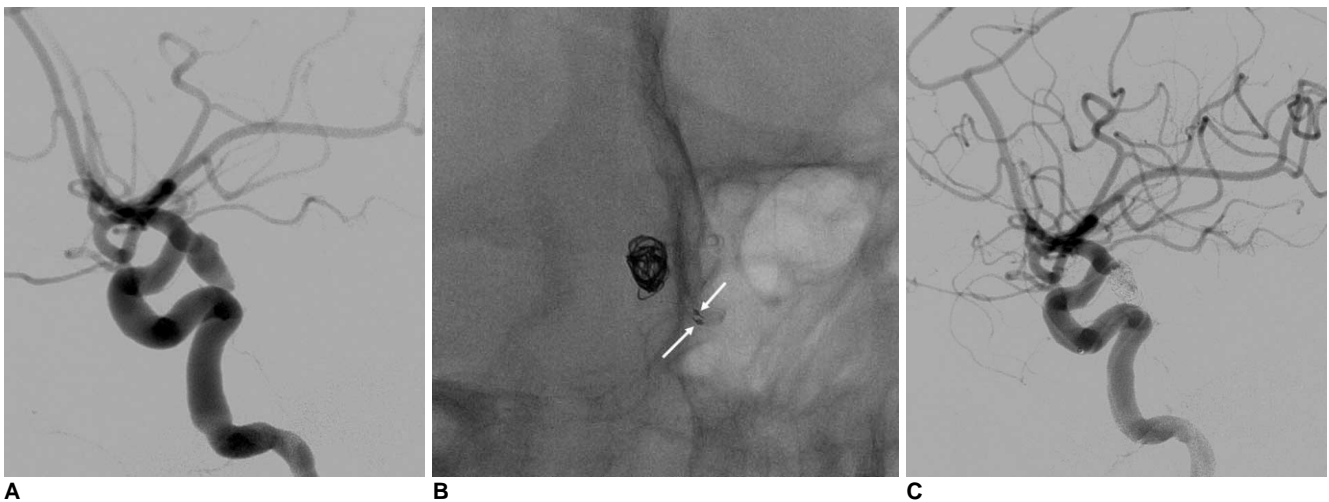
### 4. Coil Detachment

The coils are manipulated until they are presumed to be stable within the aneurysm lumen. One coil is released and the other is kept tethered to its introducer. More stable-looking coil should be detached first. Sometimes, however, the more stable-looking coil was not detached first, especially when it formed a stable



**Fig. 3.** Imaginary compartmentalization of aneurysms for double catheter methods.

- A. The inflow and outflow zone.
- B. Superficial and deep part.
- C. Multilobulated aneurysm.



**Fig. 4.** A 63-year-old woman with subarachnoid hemorrhage.

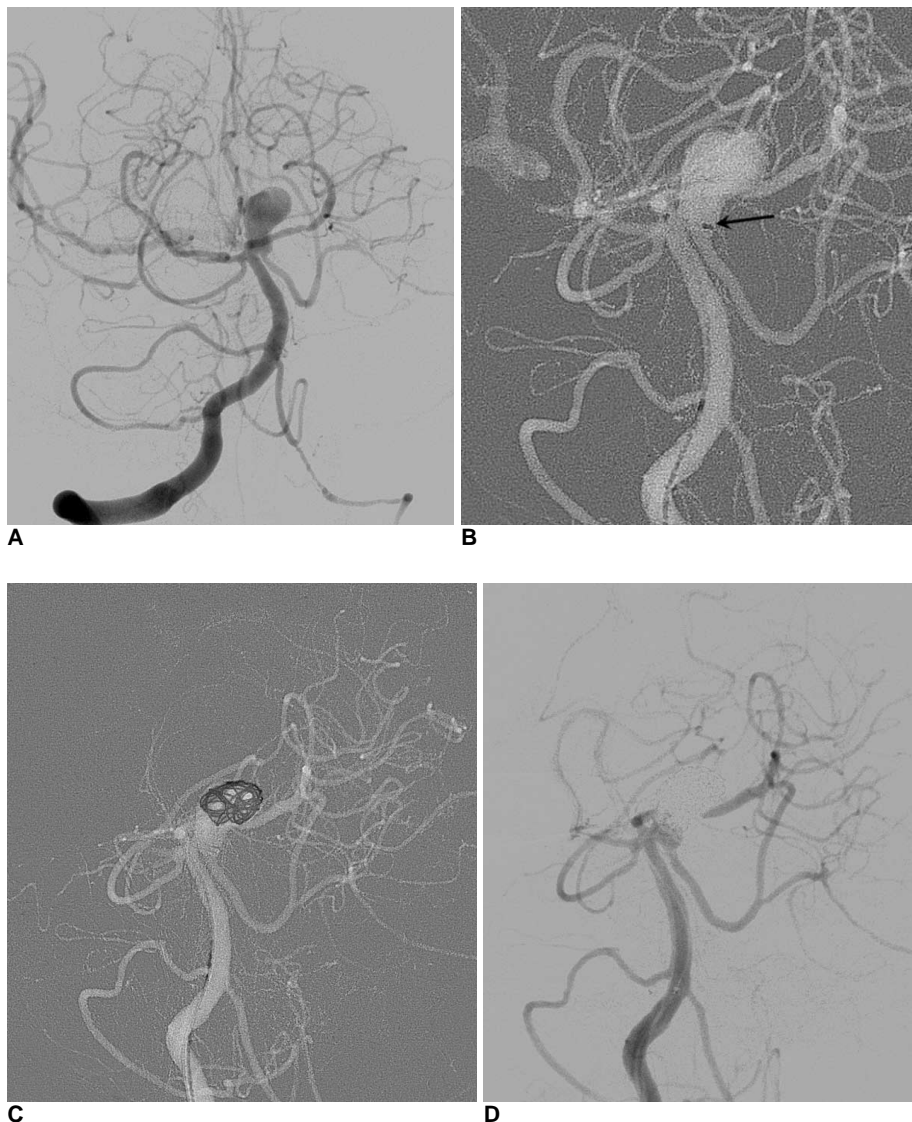
- A. Lateral projection of left carotid angiogram shows posterior communicating artery aneurysm with wide-neck.
- B. Two microcatheters (arrows) are placed within aneurysm lumen, and two coils are deployed simultaneously for intermingling of coils.
- C. Final angiogram shows obliteration of aneurysm with small residual neck.

large frame that prevented excessive movement of the second small coil, which is remained within this frame. Additional coils are then introduced through the available microcatheter until it is felt that the entire mass is stable.

If you are worry about subsequent movement of the coil mass out of the aneurysm during later coil placement, should release the more superficial coil first and leave the deeper coil attached until the end of the procedure. The increase of the volume in deep deposition of coils in this wide-necked aneurysm has the risk of pushing more superficially place coils out of the aneurysm and into the parent vessel (18). When there is any evidence of the superficial coil frame changing shape or of parent artery protrusion, the superficial framing coils should not detach prior to obtaining satisfactory aneurysm packing through the deeper positioned microcatheter (19).

In some cases, two coils may be insufficient for making a stable initial coil frame. For these aneurysms, the placement of third or fourth microcatheters within aneurismal sacs can make stable initial coil frames by intermingling three or four coils (16).

Double catheter method is potentially more versatile, theoretically allowing treatment of aneurysms not amenable to balloon remodeling or stent placement. This method is simpler than method using balloon or stent, and does not need to use guiding system with the larger diameter, and the cost is lower than the neck remodeling technique with balloon or stent. Therefore, this method is worth trying the first method for aneurysm with unfavorable configuration before the use of the balloon or stent (Fig. 4). Additionally, this method is associated with a relatively low risk of thromboembolic complications in comparison to those of balloons or stents. Therefore, there is no need to



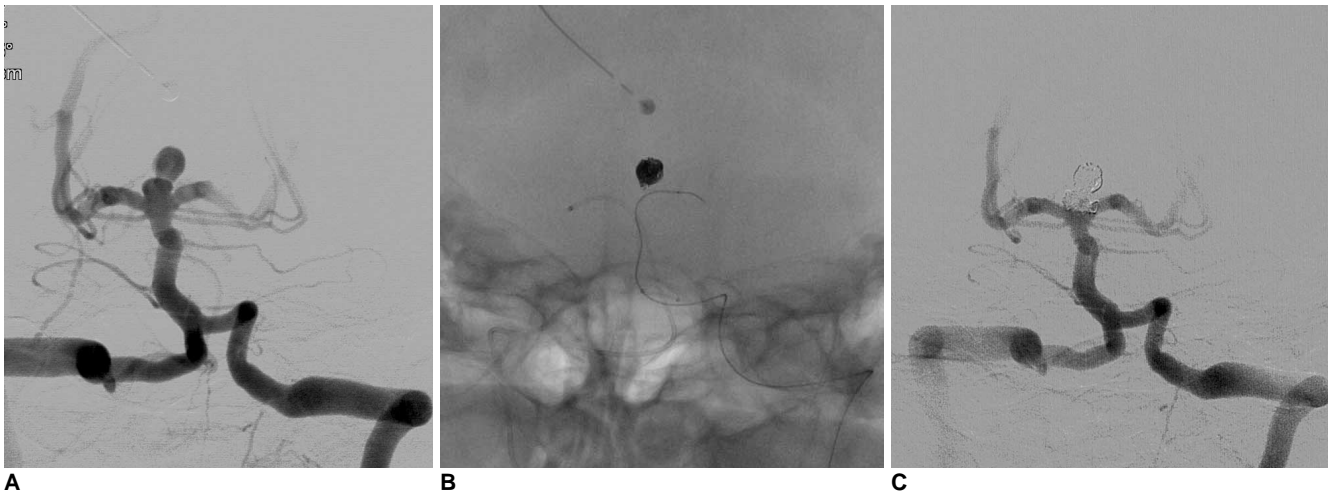
**Fig. 5.** A 60-year-old man presented with diplopia.

**A.** AP projection of right vertebral artery angiogram shows an aneurysm on left superior cerebellar artery (SCA) origin. Dome to neck ratio of this aneurysm was under 1.4, and incorporated left SCA has acute angle with the aneurysm neck.

**B.** The first microcatheter was placed across the neck of aneurysm. The tip of microcatheter is marked by arrow.

**C.** The second microcatheter was placed within aneurysm fundus, and a coil is deployed within the fundus.

**D.** Final left vertebral artery angiogram shows satisfactory occlusion of the aneurismal sac without the compromise of the left SCA.



**Fig. 6.** A 66-year-old man with subarachnoid hemorrhage.

**A.** Left vertebral artery angiogram shows basilar top aneurysm with wide-neck. This aneurysm is compartmentalized deep daughter sac and superficial fundus

**B.** The first microcatheter is placed with the aneurysm and coil embolization is performed. Coils are localized only deep daughter sac. Then, two microcatheters are placed within bilateral posterior cerebral arteries (PCAs) to protect the aneurismal neck.

**C.** Final left vertebral artery angiogram shows near complete packing of the aneurysmal sac. Although a coil loop is protruded within left posterior cerebral artery, the flow of left PCA is intact and there isn't any thromboembolic complication.

medicate antiplatelet agents (17).

There may be several potential complications associated with multiple microcatheters including thromboembolism, coil stretching, coil breakage or coil interlocking during the coil manipulation. There is a solution when coil interlocking or stretching occurs: withdrawal of coils and microcatheters together. Because no coil is detached until a stable initial coil frame is made, all coils and microcatheters can be easily retrieved together, and because a single guiding catheter is inserted, removal of the whole devices is safe as well as easy.

Kwon et al. (17) presented that the double catheter technique was feasible and safe for embolization of aneurysms with unfavorable configurations, even though the limitation of this study was its small number of patients.

## CATHETER-ASSISTED METHOD

A catheter-assisted technique is used when a balloon or a stent cannot be inserted into the incorporated branch because of its small size and/or acute angulations to the parent artery (22–24). Because the balloon and catheter delivery catheter are stiffer than the catheter for coil delivery, these may not be amenable to enter the incorporated vessel with acute angle or to pass through the tortuous proximal conducting vessels. Key concept of this technique is one microcatheter is

inserted into the incorporated branch for protection, and the tip of the other catheters is positioned into the aneurysm lumen for coil deployment (Fig. 5). This technique is also viable alternative for management of aneurysms with unfavorable wide-neck (22).

The catheter-assisted neck protection method is technically very simple. The first microcatheter for coil deployment is placed in the sac of the aneurysm. The second catheter is inserted into the incorporated branch for protection or positioned across the orifice of the aneurysm to prevent coil herniation into the parent vessel.

This technique allows free control of the microcatheter, making the irregular shape of the coil basket appropriate for preserving the incorporated branch by controlling the tension of the catheter inserted into the incorporated branch, and pushing the coil basket away from the origin of the incorporated branch during the coil deployment.

In wide-neck aneurysm, the protecting catheter should be adhered to aneurysm neck and press against coil loops. Therefore, the aneurysm neck that opens to outer curve side of the parent artery or branching artery having acute angle with parent artery is the morphologic requisite to guarantee the success of the catheter-assisted method. Aneurysm arising from paraclinoid carotid artery or basilar top usually has favorable geometry.

The technique of catheter-assisted method has several



advantages over the balloon or stent-assisted techniques. First, this method is technically easy and no additional femoral puncture is required, and one 6F guiding catheter is used as is conventional. Second, if the parent arterial flow is hindered by the herniated coil mesh, an immediate thrombolysis can be performed via the positioned microcatheter, because a microcatheter was readily available for navigating in a small and tortuous artery. Third, According to the situation, this method can easily change to double catheter method. However, microcatheter only is insufficient to protect the aneurysm neck, the combination with 3D framing coils or with double catheter technique may increase the chance of the successful procedure (Fig. 6).

## COIL-ASSISTED METHOD

Only 2 cases about the coil assisted method were officially reported (17, 23). Coil and catheter-assisted method is the modified technique of the catheter-assisted method. To protect incorporated branch from the fundus of the aneurysm, a coil is deployed first through one microcatheter near the origin of the incorporated vessel, and this coil interfere with movement of the second coil toward incorporated branch. After a stable coil frame has been formed without compromise of the incorporated branch by the second and subsequent coils, the first coil is retrieved and reinserted into the stable coil mass for sac filling.

This method can apply the case that protecting microcatheter cannot advance into the incorporated vessel. However, this method has the risk of the unexpected coil interlocking or thromboembolism.

## CONCLUSION

3D coils and various techniques using microcatheters are practically useful to manage the wide-neck aneurysms. So unlike balloon remodeling technique or stent deployment, these techniques do not lead to the flow arrest of parent artery or in-stent thrombosis, avoiding the use of antiplatelet therapy. 3D coils, double catheter and catheter-assisted methods should be considered as a viable alternative for management of aneurysms with unfavorable wide-neck or dome to neck ratios. However, these methods do not offer protection against the coil protrusion through the neck. Therefore, we should make the strategy for endovascular treatment of the wide-neck aneurysm carefully, in considering aneurysm configuration, relationship between the aneurysm and parent artery, the presence

of incorporated branch, proximal approach route, technical availability, the risk of thromboembolic complications, and antiplatelet therapy.

## References

1. Molyneux A, Kerr R, Stratton I, Sandercock P, Clarke M, Shrimpton J, Holman R. International Subarachnoid Aneurysm Trial (ISAT) of neurosurgical clipping versus endovascular coiling in 2143 patients with ruptured intracranial aneurysms: a randomised trial. *Lancet* 2002;360:1267-1274
2. Debrun GM, Aletich VA, Kehrli P, Misra M, Ausman JI, Charbel F. Selection of cerebral aneurysms for treatment using Guglielmi detachable coils: the preliminary University of Illinois at Chicago experience. *Neurosurgery* 1998;43:1281-1295; discussion 1296-1287
3. Debrun GM, Aletich VA, Kehrli P, Misra M, Ausman JI, Charbel F, et al. Aneurysm geometry: an important criterion in selecting patients for Guglielmi detachable coiling. *Neurol Med Chir (Tokyo)* 1998;38 Suppl:1-20
4. Fernandez Zubillaga A, Guglielmi G, Vinuela F, Duckwiler GR. Endovascular occlusion of intracranial aneurysms with electrically detachable coils: correlation of aneurysm neck size and treatment results. *AJNR Am J Neuroradiol* 1994;15:815-820
5. Moret J, Cognard C, Weill A, Castaings L, Rey A. Reconstruction technic in the treatment of wide-neck intracranial aneurysms. Long-term angiographic and clinical results. Apropos of 56 cases. *J Neuroradiol* 1997;24:30-44
6. Baldi S, Mounayer C, Pötin M, Spelle L, Moret J. Balloon-assisted coil placement in wide-neck bifurcation aneurysms by use of a new, compliant balloon microcatheter. *AJNR Am J Neuroradiol* 2003;24:1222-1225
7. Wanke I, Doerfler A, Schoch B, Stolke D, Forsting M. Treatment of wide-necked intracranial aneurysms with a self-expanding stent system: initial clinical experience. *AJNR Am J Neuroradiol* 2003; 24:1192-1199
8. Biondi A, Janardhan V, Katz JM, Salvaggio K, Riina HA, Gobin YP. Neuroform stent-assisted coil embolization of wide-neck intracranial aneurysms: strategies in stent deployment and midterm follow-up. *Neurosurgery* 2007; 61:460-468; discussion 468-469
9. Cloft HJ, Joseph GJ, Tong FC, Goldstein JH, Dion JE. Use of three-dimensional Guglielmi detachable coils in the treatment of wide-necked cerebral aneurysms. *AJNR Am J Neuroradiol* 2000; 21:1312-1314
10. Vallee JN, Pierot L, Bonafe A, Turjman F, Flandroy P, Berge J, et al. Endovascular treatment of intracranial wide-necked aneurysms using three-dimensional coils: predictors of immediate anatomic and clinical results. *AJNR Am J Neuroradiol* 2004;25:298-306
11. Lee DH, Arat A, Morsi H, Jou LD, Mawad ME. Embolization of Cerebral Aneurysms with Spherically Shaped Detachable Microcoils (MicroSphere Microcoil System). A Single Centre Experience. *Interv Neuroradiol* 2009;15:29-36
12. Lubicz B, Leclerc X, Gauthier JY, Lejeune JP, Pruvo JP. Three-dimensional packing with complex orbit coils for the endovascular treatment of intracranial aneurysms. *AJNR Am J Neuroradiol* 2005;26:1342-1348
13. Higashida RT, Cognard C, Bracard S. Initial clinical experience with a new complex-shaped detachable platinum coil system for

- the treatment of intracranial cerebral aneurysms. The Cordis Trufill DCS Detachable Coil System. *Interv Neuroradiol* 2006;12:123-130
14. Taschner CA, Leclerc X, Gauvrit JY, Kerkeni A, El-Mahdy M, Lejeune JP, et al. Safety of endovascular treatment of intracranial aneurysms with a new, complex shaped Guglielmi detachable coil. *Neuroradiology* 2007;49:761-766
  15. Baxter BW, Rosso D, Lownie SP. Double microcatheter technique for detachable coil treatment of large, wide-necked intracranial aneurysms. *AJNR Am J Neuroradiol* 1998;19:1176-1178
  16. Kwon OK, Kim SH, Oh CW, Han MH, Kang HS, Kwon BJ, et al. Embolization of wide-necked aneurysms with using three or more microcatheters. *Acta Neurochir (Wien)* 2006;148:1139-1145; discussion 1145
  17. Kwon OK, Kim SH, Kwon BJ, Kang HS, Kim JH, Oh CW, et al. Endovascular treatment of wide-necked aneurysms by using two microcatheters: techniques and outcomes in 25 patients. *AJNR Am J Neuroradiol* 2005;26:894-900
  18. Horowitz M, Gupta R, Jovin T. The dual catheter technique for coiling of wide-necked cerebral aneurysms. An under-reported method. *Interv Neuroradiol* 2005;11:155-160
  19. Kwon SC, Shin YS, Kim HS, Kim SY. A double catheter technique for elongated middle cerebral artery bifurcation aneurysm. A case report. *Interv Neuroradiol* 2006;12:41-44
  20. Nakahara T, Kutsuna M, Yamanaka M, Sakoda K. Coil embolization of a large, wide-necked aneurysm using a double coil-delivered microcatheter technique in combination with a balloon-assisted technique. *Neurol Res* 1999;21:324-326
  21. Kai Y, Hamada J, Morioka M, Yano S, Mizuno T, Kuratsu J. Double microcatheter technique for endovascular coiling of wide-neck aneurysms using a new guiding device for the transcarotid approach: technical note. *Neuroradiology* 2005;47:73-77
  22. Ihn YK, Kim DI, Kim BS, Lee JM. Utility of catheter-assisted Guglielmi detachable coiling in the treatment of wide-necked aneurysms. *Acta Neurochir (Wien)* 2006;148:1045-1052; discussion 1052
  23. Kim BM, Park SI, Kim DJ, Kim DI, Suh SH, Kwon TH, et al. Endovascular coil embolization of aneurysms with a branch incorporated into the sac. *AJNR Am J Neuroradiol* 2010;31:145-151
  24. Sheen SH, Jung CK, Cho JH, Kwon BJ, Han MH. Microcatheter-assisted coil embolization of distal vertebral artery wide-necked aneurysm: a case report. *Neurointervention* 2007;2:56-59

신경중재치료의학 2010;5:71-78

## 광경동맥류의 혈관내 중재치료: 코일과 미세카테터의 응용

<sup>1</sup>경희대학교 의과대학 강동경희대학병원 영상의학과, <sup>2</sup>신경외과  
<sup>3</sup>경희대학교 의과대학 경희의료원 영상의학과

류창우<sup>1</sup> · 고준석<sup>2</sup> · 이철영<sup>2</sup> · 김의중<sup>3</sup>

코일을 이용한 뇌혈관 동맥류의 치료에서 가장 중요한 제한점이 상대적으로 넓은 경부이다. 그러나 스텐트나 풍선을 이용한 모혈관의 경부를 보호하는 기법이 개발되어 넓은 경부 동맥류의 혈관내 치료의 제한이 상당히 극복되었으나 해부학적, 또는 기술적인 원인 등으로 인해 이마저도 제한 받을 수 있는 경우가 있다. 그러나 삼차원 코일이나 미세카테터를 이용한 방법을 사용한다면 경부 보호기구가 없이도 넓은 경부 동맥류의 혈관내 치료가 가능하다. 저자들은 경부 보호기구 사용법의 대안으로서 삼차원 코일, 이중카테터기법, 카테터지지기법을 소개하고 구체적 적응증, 응용방법, 장점 등에 대하여 설명하였다. 이러한 방법들은 스텐트나 풍선을 이용한 경부 보호법보다 기술적으로 용이하고 혈전합병증의 가능성이 적으나 코일의 돌출을 충분히 막을 수 없는 것이 단점이다. 따라서 넓은 경부 동맥류를 안전하고 효과적으로 치료하기 위해서는 동맥류의 형태, 접근 방법, 기술적 가능성, 혈전합병증의 가능성 등을 충분히 고려하여 치료방법을 선택하는 것이 바람직하다.

**Key Words :** Aneurysm; Endovascular therapy; Microcatheter; Coil